

## Case Report

# Apical Ballooning Syndrome: A Complication of Dual Chamber Pacemaker Implantation

Raed A. H. Abu Sham'a MD, Elad Asher MD, David Luria MD, Michael Berger MD, Michael Glikson MD, FACC, FESC

The Heart Institute, Chaim Sheba Medical Center, Tel Hashomer, and the Sackler Faculty of Medicine, Tel Aviv University, Israel.

Address for correspondence: Michael Glikson, MD, FACC, FESC, Electrophysiology and Pacing Unit, Heart Institute, Chaim Sheba Medical Center, 52 621 Tel Hashomer, Israel. E-mail: [mglkson/at/post.tau.ac.il](mailto:mglkson/at/post.tau.ac.il)

### Abstract

Apical ballooning is a cardiac syndrome (Takotsubo Cardiomyopathy) described as a typical form of acute transient left ventricular dysfunction. While its onset has often been associated with emotionally or physically stressful situations, it has an overall favorable prognosis. We describe here a case of transient apical ballooning following permanent pacemaker implantation.

**Key words:** Pacemaker; Apical ballooning

### Introduction

Apical ballooning syndrome (ABS) is a novel cardiac syndrome described recently as a typical form of acute transient left ventricular (LV) dysfunction associated with chest pain, ECG changes, and mild enzyme elevation without coronary occlusion [1]. While its onset has often been associated with emotionally or physically stressful situations, gradual recovery of LV dysfunction is the rule, and the overall prognosis is favorable. However, it could sometimes be associated with hemodynamic compromise and in rare cases may lead to serious complications and death [1, 2]. We describe here a case of transient ABS following permanent pacemaker implantation.

### Case Report

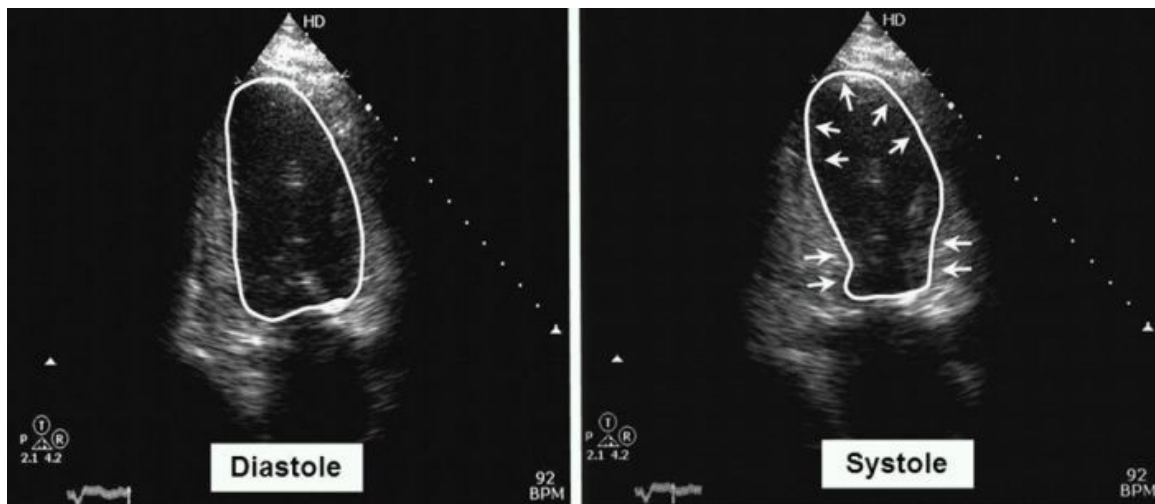
An 86 year old female, with no significant past medical history or cardiac symptoms, with the exception of a successful ablation of AVNRT 12 years ago, was admitted with recurrent syncope. She underwent a detailed evaluation, including an ECG and echocardiography, both of which were normal, with an estimated left ventricle ejection fraction (LVEF) of 60%. She was diagnosed by bedside monitoring to have intermittent complete AV block with ventricular escape rhythm of approximately 30 bpm.

She underwent implantation of a dual chamber pacemaker. The procedure was smooth with no apparent complications. On the night following implantation she started complaining of dyspnea and orthopnea which resolved spontaneously. She was discharged the following morning after

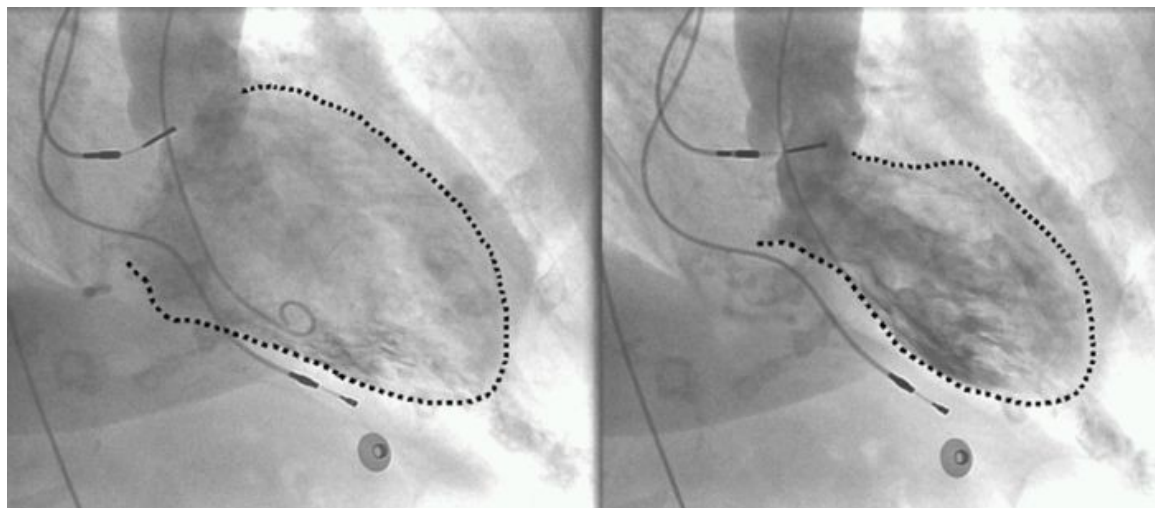
pacemaker evaluation and chest X-ray, both of which were normal. Several hours later, however, she developed acute pulmonary edema. Emergency room ECG showed atrial synchronous ventricular pacing of approximately 80bpm, prolongation of the QTc interval up to 540 ms and

**Raed A H Abu Sham'a, Elad Asher, David Luria, Michael Berger, Michael Glikson, 230**  
**“Apical Ballooning Syndrome: A Complication of Dual Chamber Pacemaker Implantation”**

non-specific ST-T changes. Echocardiography revealed normal left ventricle size, normal basal segment contraction with severe global left ventricular dysfunction and an estimated LVEF of 20%. The echocardiographic picture was typical of apical ballooning (Figure 1). Troponin I level was mildly elevated at 0.12 micg/L, (normal <0.07). The patient was managed conservatively; coronary angiography was performed after stabilization which showed normal coronary arteries, and left ventriculogram confirmed the diagnosis of ABS (Figure 2).



**Figure 1:** Echocardiogram clearly showing apical ballooning during systole with normal contraction of the basal segments (arrows).



**Figure 2:** Left ventriculogram showing apical ballooning during systole with normal contraction of the basal segments (arrows).

Over the next several days there was a dramatic improvement in her clinical condition, and a gradual recovery of LVEF on repeated echocardiograms. Repeated echocardiography after five days demonstrated an LVEF of 45%. She was discharged in stable condition and follow-up echocardiography demonstrated complete recovery of left ventricular function.

## Discussion

Apical ballooning syndrome was first described in Japan in early 1990s [3], where it was named Takotsubo Cardiomyopathy, due to the similarity between the dilated LV and an ancient Raed A H Abu Sham'a, Elad Asher, David Luria, Michael Berger, Michael Glikson, 231  
*“Apical Ballooning Syndrome: A Complication of Dual Chamber Pacemaker Implantation”*

Japanese fishing pot used to trap (tsubo) octopuses (tako). Earlier reports described such cases without applying the title of ABS [4, 5]. Although the exact mechanism of this syndrome is unknown, it is thought to be due to excess catecholamine release, mainly norepinephrine, in stressful physical or psychological conditions and is thus named stress-induced cardiomyopathy [5,6]. Alternatively, it could be due to transient coronary occlusion by spasm or ruptured plaque. However, the distribution of the affected areas does not follow a specific coronary artery anatomy, and coronary angiogram failed to show any evidence of plaque rupture or spasm even in patients with persistent ST-segment elevation [7].

Pacemaker implantation could be associated with a number of acute complications related to the procedure, the patient and/or the device itself. However, we are aware of only three previous cases of ABS reported in the literature following pacemaker implantation [11-13]. In our case, there was no other cause for acute deterioration of LV function, and the diagnosis of apical ballooning syndrome was made and confirmed by applying the Mayo Clinic diagnostic criteria [14]. The classical course of gradual and complete resolution of the regional wall abnormalities and normalization of the LVEF at follow-up, helped to confirm the diagnosis. Notably, diagnosis may be more difficult in the absence of ECG changes that are masked by pacing, as was demonstrated in this case. We conclude that arrhythmia device implantation represents psychophysical stress that may be complicated by apical ballooning.

## References

1. Tsuchihashi K, Ueshima K, Uchida T, Oh-mura N, Kimura K, Owa M, Yoshiyama M et al. Transient Left Ventricular Apical Ballooning without Coronary Artery Stenosis: A Novel Heart Syndrome Mimicking Acute Myocardial Infarction. *J Am Coll Cardiol*. 2001;38:11-8.
2. Gianni M, Dentali F, Grandi AM, Sumner G, Hiralal R, Lonn E. Apical ballooning syndrome or takotsubo cardiomyopathy: a systematic review. *Eur Heart J*. 2006;27:1523-9.
3. Dote K, Sato H, Tateishi H, Uchida T, Ishihara M. Myocardial stunning due to simultaneous multivessel coronary spasm: a review of 5 cases. *J Cardiol* 1991;21:203-14.
4. Kemp HG, Elliott WC, Gorlin R. The anginal syndrome with normal coronary arteriography. *Trans Assoc Am Phys* 1967;17:1471–822.
5. Cocco G, Chu D. Stress-induced cardiomyopathy: A review. *Eur J Inter Med*. 2007; 18: 369–379.
6. Jeffrey B. Jensen, Joseph F. Malouf T. Takotsubo cardiomyopathy following cholecystectomy: A poorly recognized cause of acute reversible left ventricular dysfunction. *Int J Cardiol*. 2006; 106: 390– 391.
7. Ibanez B, Navarro F, Cordoba M, M-Alberca P, Farre J. Tako-tsubo transient left ventricular apical ballooning: is intravascular ultrasound the key to resolve the enigma? *Heart* 2005; 91: 102–4.
8. Ogura R, Hiasa Y, Takahashi T, Yamaguchi K, Fujiwara K, Ohara Y, Nada T et al. Specific

findings of the standard 12-lead ECG in patients with 'Takotsubo' cardiomyopathy: comparison with the findings of acute anterior myocardial infarction. *Circ J* 2003; 67:687–90.

9. Akashi YJ, Barbaro G, Sakurai T, Nakazawa K and Miyake F. Cardiac autonomic imbalance  
**Raed A H Abu Sham'a, Elad Asher, David Luria, Michael Berger, Michael Glikson, 232**  
**“Apical Ballooning Syndrome: A Complication of Dual Chamber Pacemaker Implantation”**

in patients with reversible ventricular dysfunction takotsubo cardiomyopathy. *Q J Med* 2007; 100:335–343.

10. Wittstein IS, Thiemann DR, Lima JA, Baughman KL, Schulman SP, Gerstenblith G, Wu KC et al. Neurohumoral features of myocardial stunning due to sudden emotional stress. *N Eng J Med* 2005;352:539–48.

11. Kimura K, Tanabe-Hayashi Y, Noma S, Fukuda K. Rapid Formation of Left Ventricular Giant Thrombus With Takotsubo Cardiomyopathy. *Circulation*. 2007;115: e620-e621.

12. Chun SG, Kwok V, Pang DK, Lau TK. Transient left ventricular apical ballooning syndrome (takotsubo cardiomyopathy) as a complication of permanent pacemaker implantation. *Int J Cardiol*. 2007; 117: e27–e30.

13. Kurisu S, Inoue I, Kawagoe T, Ishihara M, Shimatani Y, Hata T, Nakama Y et al. Persistent left ventricular dysfunction in takotsubo cardiomyopathy after pacemaker implantation. *Circ J*. 2006;70:641-4.

14. Bybee KA, Kara T, Prasad A, Lerman A, Barsness GW, Wright RS, Rihal CS. Systematic review: transient left ventricular apical ballooning: a syndrome that mimics ST-segment elevation myocardial infarction. *Ann Intern Med*. 2004;141:858-65.