

Editorial

Idiopathic Fascicular Ventricular Tachycardia

Johnson Francis, MD, DM*, Venugopal K, MD, DM[†], Khadar SA, MD, DM[‡], Sudhayakumar N, MD, DM[§], Anoop K. Gupta MD, DM, DNB, FACC^{||}

*Associate Professor, [†] Professor & Head, [‡]Professor, Department of Cardiology, Medical College Calicut, Kerala, India.

[§]Professor & Head, Department of Cardiology, Medical College Kottayam, Kerala, India.

^{||}Consultant Cardiologist and Chief Electrophysiologist, Apollo Hospital, Ahmedabad, India.

Address for correspondence: Dr. Johnson Francis, MD, DM, Pulikkottil, Thodayad, Chevarambalam P.O., Calicut -17, Kerala, India. 673 017. Email: pulikkottil2002@hotmail.com

Abstract:

Idiopathic fascicular ventricular tachycardia is an important cardiac arrhythmia with specific electrocardiographic features and therapeutic options. It is characterized by relatively narrow QRS complex and right bundle branch block pattern. The QRS axis depends on which fascicle is involved in the re-entry. Left axis deviation is noted with left posterior fascicular tachycardia and right axis deviation with left anterior fascicular tachycardia. A left septal fascicular tachycardia with normal axis has also been described. Fascicular tachycardia is usually seen in individuals without structural heart disease. Response to verapamil is an important feature of fascicular tachycardia. Rare instances of termination with intravenous adenosine have also been noted. A presystolic or diastolic potential preceding the QRS, presumed to originate from the Purkinje fibers can be recorded during sinus rhythm and ventricular tachycardia in many patients with fascicular tachycardia. This potential (P potential) has been used as a guide to catheter ablation. Prompt recognition of fascicular tachycardia especially in the emergency department is very important. It is one of the eminently ablatable ventricular tachycardias. Primary ablation has been reported to have a higher success, lesser procedure time and fluoroscopy time.

Key words: Ventricular Tachycardia, Structural Normal Heart, Radiofrequency ablation.

Introduction

In general ventricular tachycardias have wide QRS complexes. One of the earliest descriptions of ventricular tachycardia (VT) with a narrow QRS complex was by Cohen et al in 1972.¹ Their description was a left posterior fascicular tachycardia with relatively narrow QRS. In 1979, Zipes et al² reported three patients with ventricular tachycardia characterized by QRS width of 120 to 140 ms, right bundle branch block morphology and left-axis deviation. These patients were young and had no major cardiac abnormalities. The arrhythmia could be induced by exercise, atrial and ventricular premature beats as well as atrial pacing and ventricular pacing. Belhassen et al observed that this tachycardia can be terminated by the calcium channel blocker verapamil³ This observation has been confirmed subsequently by others as well.^{4,5,6,7} Belhassen

et al proposed that this is a specific ECG-electrophysiological entity.⁸ Fascicular tachycardia has also been called Idiopathic Left Ventricular Tachycardia (ILVT) by other authors, though left ventricular outflow tract VT also comes under the purview of this term.^{9,10} Fascicular tachycardia is usually paroxysmal, but a case which was persistent, leading to cardiac enlargement and complete resolution following therapy with verapamil has also been reported.⁴ Termination of idiopathic fascicular ventricular tachycardia by vagal maneuvers was noted in 4 cases by Buja et al.¹¹ Successful radiofrequency catheter ablation was described by Klein et al.¹² In this article we propose to review the current status of our knowledge regarding the genesis and treatment of idiopathic fascicular ventricular tachycardia.

Mechanism and Classification

Zipes et al postulated that the origin of the tachycardia was localized to a small region of reentry or triggered automaticity located in the posteroinferior left ventricle, close to the posterior fascicle of the left bundle branch.² Response to verapamil suggested a role for the slow inward calcium channel in the genesis of the arrhythmia. Endocardial mapping during tachycardia revealed the earliest activation at the ventricular apex and mid septum.¹³ The tachycardia can be entrained by ventricular and atrial pacing. Entrainment by atrial pacing suggests easy access over the conduction system into the reentry circuit and hence a role for the fascicles in the reentrant circuit.¹⁴ Lau suggested the origin as reentry circuits involving the lower septum or posterior part of the left ventricle close to the endocardial surface in view of the response to radiofrequency ablation in these sites.¹⁵ Purkinje potential recorded in the diastolic phase during VT at the mid-anterior left ventricular septum in rare cases with RBBB pattern and right axis deviation suggested origin near left anterior fascicle in those cases.¹⁶

Recently Kuo et al has questioned the involvement of the fascicle of the left bundle branch in ILVT.¹⁷ They studied two groups of patients with ILVT. One with left anterior or posterior fascicular block during sinus rhythm and the other without. They noted that the transition zone of QRS complexes in the precordial leads were similar during VT in both groups. New fascicular blocks did not appear after ablation. Therefore they concluded that the fascicle of the left bundle branch may not be involved in the anterograde limb of reentrant circuit in ILVT.

Fascicular tachycardia has been classified into three subtypes: (1) left posterior fascicular VT (**Figure 1**) with a right bundle branch block (RBBB) pattern and left axis deviation (common form); (2) left anterior fascicular VT with RBBB pattern and right-axis deviation (uncommon form); and (3) upper septal fascicular VT with a narrow QRS and normal axis configuration (rare form).¹⁸

Anatomical Substrate

Endocardial activation mapping during VT identifies the earliest site in the region of the infero-posterior left ventricular septum. This finding, along with VT morphology and short retrograde VH interval suggests a left posterior fascicular origin. Nakagawa and colleagues¹⁹ recorded high-frequency potentials preceding the site of earliest ventricular activation during the VT and sinus rhythm. These potentials are thought to represent activation of Purkinje fibers and are recorded from the posterior one third of the left ventricular septum. Successful RF ablation is achieved at sites where the Purkinje potential is recorded 30 to 40 ms before the VT QRS complex.

Some data suggest that the tachycardia may originate from a false tendon or fibromuscular band that extends from the posteroinferior left ventricle to the basal septum.²⁰ Histological examination of false tendon disclosed abundant Purkinje fibers.

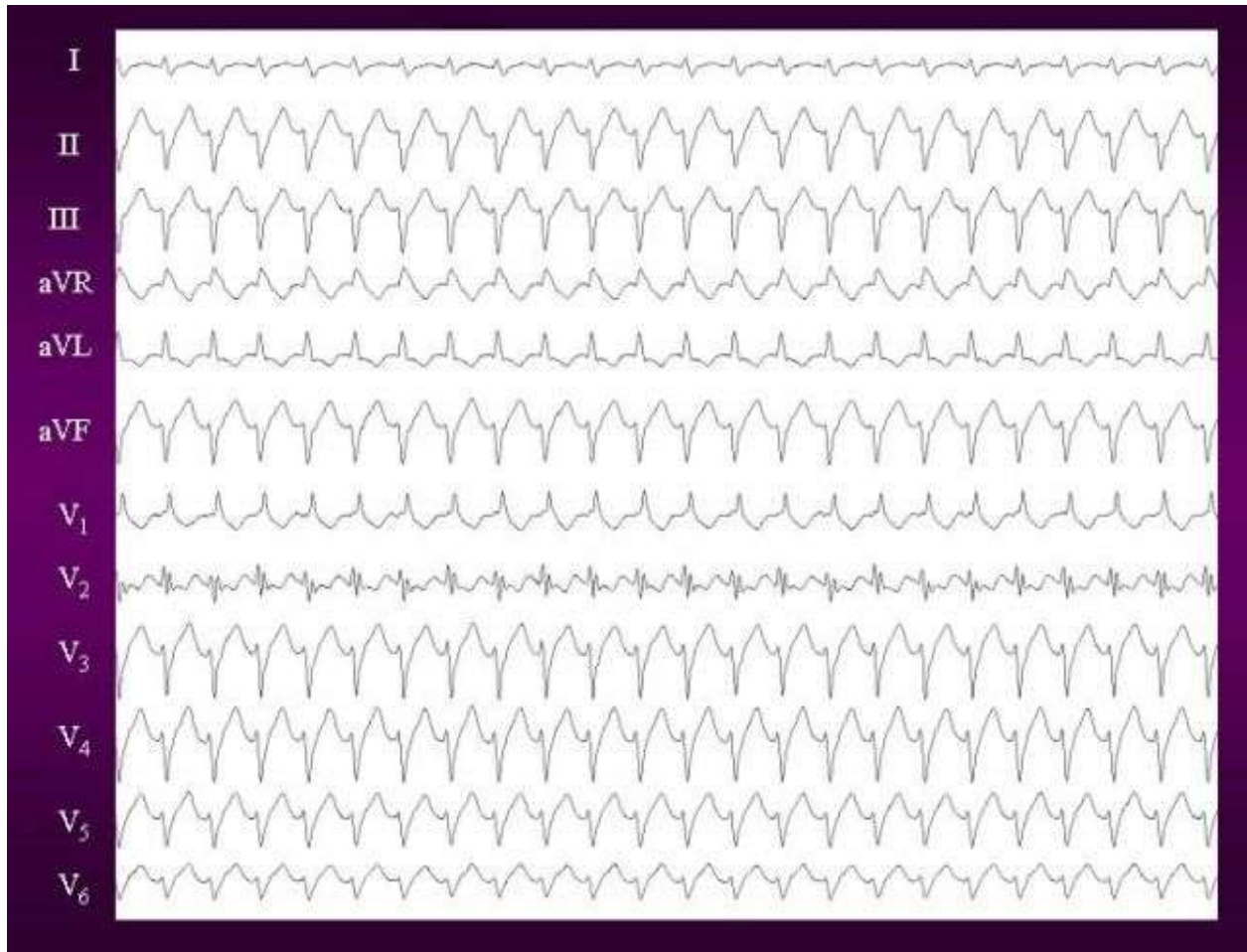


Figure 1. 12 lead ECG of Idiopathic left ventricular tachycardia. It shows classical RBBB with leftward axis morphology suggestive of posterior fascicle origin.

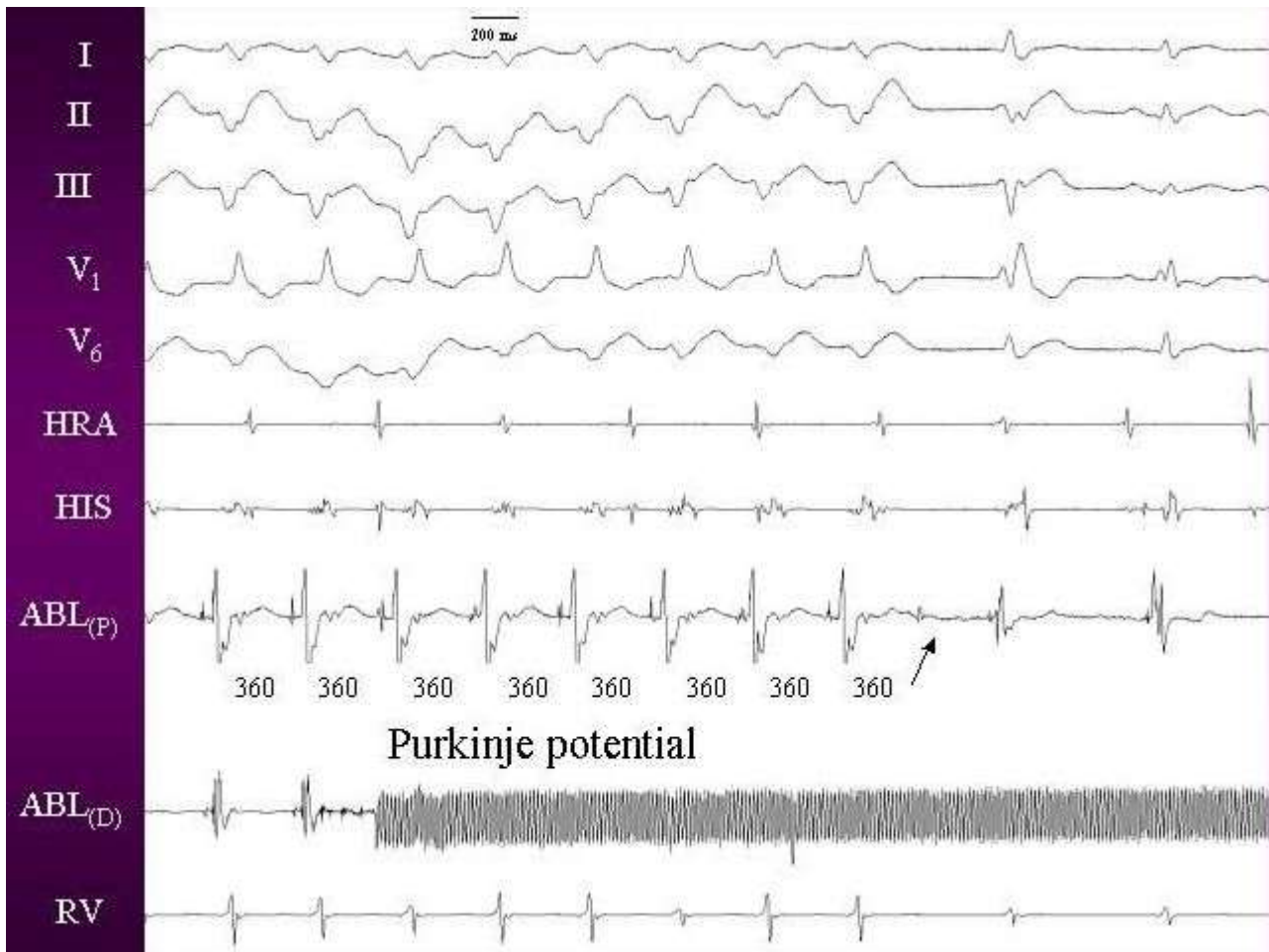
Electrophysiological Study

Fascicular tachycardia can be induced by programmed atrial or ventricular stimulation in most cases. Isoprenaline infusion may be required in certain cases; rarely there may be difficulty in induction despite isoprenaline infusion. Endocardial mapping identifies the earliest activation in the posteroapical left ventricular septum in patients with posterior fascicular tachycardia.

A high frequency potential with short duration, preceding the QRS has been described as the Purkinje potential (**Figure 2**). This has also been called P potential and diastolic potential. P potentials can be recorded both in sinus rhythm and during ventricular tachycardia. Pacing at sites manifesting the earliest P potential produces QRS complexes identical to that of the clinical tachycardia.¹⁹

Pharmacological Therapy

Intravenous verapamil is effective in terminating the tachycardia. However the efficacy of oral verapamil in preventing tachycardia relapse is variable. Good response and resolution of tachycardiomyopathy with verapamil treatment was noted by Toivonen et al⁴, while Chiaranda et



Figures 2. Intracardia electrogram during tachycardia showing purkinje potential, which persisted after the ablation also (arrow).

al commented on the poor efficacy.²¹ Treatment with propranolol has also resulted in cure of arrhythmia and resolution of features of tachycardiomyopathy in another case with incessant fascicular VT.²² Though fascicular tachycardias do not generally respond to adenosine, termination of VT originating from the left anterior fascicle by intravenous adenosine has been documented.²³

Catheter Ablation

The young age of most patients with need for long-term antiarrhythmic treatment and attendant side effects prompted the search for curative therapies. Fontaine et al (1987) described successful treatment of ILVT by application of a high-energy DC shock (fulguration) between the catheter tip and a neutral plate placed under the patient's back.²⁴ Klein et al (1992) reported cure of ILVT by radiofrequency catheter ablation.²⁵ Since then radiofrequency has remained the procedure of choice.

Different approaches for radiofrequency ablation have been described by various authors. Nakagawa et al preferred careful localization of the Purkinje potential in guiding ablation. They selected the area where a Purkinje potential precedes the QRS complex during tachycardia.¹⁹ Wellens et recommend pace mapping with a match between the 12 simultaneously recorded ECG leads during pacing and the clinical tachycardia for localizing the site of ablation.⁹ They

hypothesize that pathways within the Purkinje network that are not included in the reentry circuit responsible for the tachycardia may also become activated. Ablation of those regions may not result in interruption of the tachycardia circuit.

Primary Radiofrequency Ablation

Since fascicular VT is sometimes difficult to induce despite pharmacological provocation, some workers (Gupta et al) prefer primary ablation. In a recent report, seven cases of incessant fascicular VT were successfully ablated with no recurrence.²⁶ They reported a shorter procedure time, significantly lower fluoroscopy time and lesser number of radiofrequency energy deliveries in the primary versus elective groups. The longer procedural time during elective ablation was mainly due to the time spent in induction of fascicular VT.

References

1. Cohen HC, Gozo EG Jr, Pick A. Ventricular tachycardia with narrow QRS complexes (left posterior fascicular tachycardia). *Circulation*. 1972 May; 45(5): 1035-43.
2. Zipes DP, Foster PR, Troup PJ, Pedersen DH. Atrial induction of ventricular tachycardia: reentry versus triggered automaticity. *Am J Cardiol*. 1979; 44:1-8.
3. Belhassen B, Rotmensch HH, Laniado S. Response of recurrent sustained ventricular tachycardia to verapamil. *Br Heart J*. 1981 Dec; 46(6): 679-82.
4. Toivonen L, Nieminen M. Persistent ventricular tachycardia resulting in left ventricular dilatation treated with verapamil. *Int J Cardiol*. 1986; 13(3): 361-5.
5. Tai YT, Chow WH, Lau CP, Yau CC. Verapamil and ventricular tachycardias. *Chin Med J (Engl)*. 1991 Jul; 104(7): 567-72.
6. Ward DE, Nathan AW, Camm AJ. Fascicular tachycardias sensitive to calcium antagonists. *Eur Heart J*. 1984;5:896-905.
7. Sethi KK, Manoharan S, Mohan JC, Gupta MP. Verapamil in idiopathic ventricular tachycardia of right bundle-branch block morphology: observations during electrophysiological and exercise testing. *Pacing Clin Electrophysiol*. 1986;9:8-16.
8. Belhassen B, Shapira I, Pelleg A, Copperman I, Kauli N, Laniado S. Idiopathic recurrent sustained ventricular tachycardia responsive to verapamil: an ECG-electrophysiologic entity. *Am Heart J*. 1984 Oct; 108(4 Pt 1): 1034-7.
9. Wellens HJJ, Smeets JLRM. Idiopathic Left Ventricular Tachycardia: Cure by Radiofrequency Ablation. *Circulation*. 1993; 88(6): 2978-2979.
10. Thakur RK, Klein GJ, Sivaram CA et al. Anatomic Substrate for Idiopathic Left Ventricular Tachycardia. *Circulation*. 1996;93:497-501.
11. Buja G, Folino A, Martini B et al. Termination of idiopathic ventricular tachycardia with QRS morphology of right bundle branch block and anterior fascicular hemiblock (fascicular tachycardia) by vagal maneuvers. Presentation of 4 cases. *G Ital Cardiol*. 1988 Jul; 18(7): 560-6.

12. Klein LS, Shih H, Hackett FK, Zipes DP, Miles WM. Radiofrequency catheter ablation of ventricular tachycardia in patients without structural heart disease. *Circulation*. 1992;85:1666-1674.
13. German LD, Packer DI, Bardy GH, Gallagher JJ. Ventricular tachycardia induced by atrial stimulation in patients without symptomatic cardiac disease. *Am J Cardiol*. 1983;52:1202-1207.
14. Okumura K, Matsuyama K, Miyagi II, Tsuchiya T, Yasue H. Entrainment of idiopathic ventricular tachycardia of left ventricular origin with evidence for re-entry with an area of slow conduction and effect of verapamil. *Am J Cardiol*. 1988;62:727-732.
15. Lau CP. Radiofrequency ablation of fascicular tachycardia: efficacy of pace-mapping and implications on tachycardia origin. *Int J Cardiol*. 1994 Oct; 46(3): 255-65.
16. Nogami A, Naito S, Tada H et al. Verapamil-sensitive left anterior fascicular ventricular tachycardia: results of radiofrequency ablation in six patients. *J Cardiovasc Electrophysiol*. 1998 Dec; 9(12): 1269-78.
17. Kuo JY, Tai CT, Chiang CE et al. Is the fascicle of left bundle branch involved in the reentrant circuit of verapamil-sensitive idiopathic left ventricular tachycardia? *Pacing Clin Electrophysiol*. 2003 Oct; 26(10): 1986-92.
18. Nogami A. Idiopathic left ventricular tachycardia: assessment and treatment. *Card Electrophysiol Rev*. 2002 Dec; 6(4): 448-57.
19. Nakagawa H, Beckman KJ, McClelland JH, et al. Radiofrequency catheter ablation of idiopathic left ventricular tachycardia guided by a Purkinje potential. *Circulation*. 1993;88:2607-2617.
20. Kudoh Y, Hiraga Y, Iimura O. Benign ventricular tachycardia in systemic sarcoidosis--a case of false tendon. *Jpn Circ J*. 1988 Apr; 52(4): 385-9.
21. Chiaranda G, Di Guardo G, Gulizia M, Lazzaro A, Regolo T. *Ital Heart J*. 2001 Nov; 2(11 Suppl): 1181-6.
22. Anselme F, Boyle N, Josephson M. Incessant fascicular tachycardia: a cause of arrhythmia induced cardiomyopathy. *Pacing Clin Electrophysiol*. 1998; 21: 760-3.
23. Kassotis J, Slesinger T, Festic E, Voigt L, Reddy CV. Adenosine-sensitive wide-complex tachycardia: an uncommon variant of idiopathic fascicular ventricular tachycardia--a case report. *Angiology*. 2003 May-Jun; 54(3): 369-72.
24. Fontaine G, Tonet JL, Frank R et al. Treatment of resistant ventricular tachycardia by endocavitary fulguration associated with anti-arrhythmic therapy. *Eur Heart J*. 1987 Aug; 8 Suppl D: 133-41.
25. Klein LS, Shih H, Hackett FK, Zipes DP, Miles WM. Radiofrequency catheter ablation of ventricular tachycardia in patients without structural heart disease. *Circulation*. 1992;85:1666
26. Gupta AK, Kumar AV, Lokhandwala YY et al. Primary radiofrequency ablation for incessant idiopathic ventricular tachycardia. *Pacing Clin Electrophysiol*. 2002 Nov; 25(11): 1555-60.